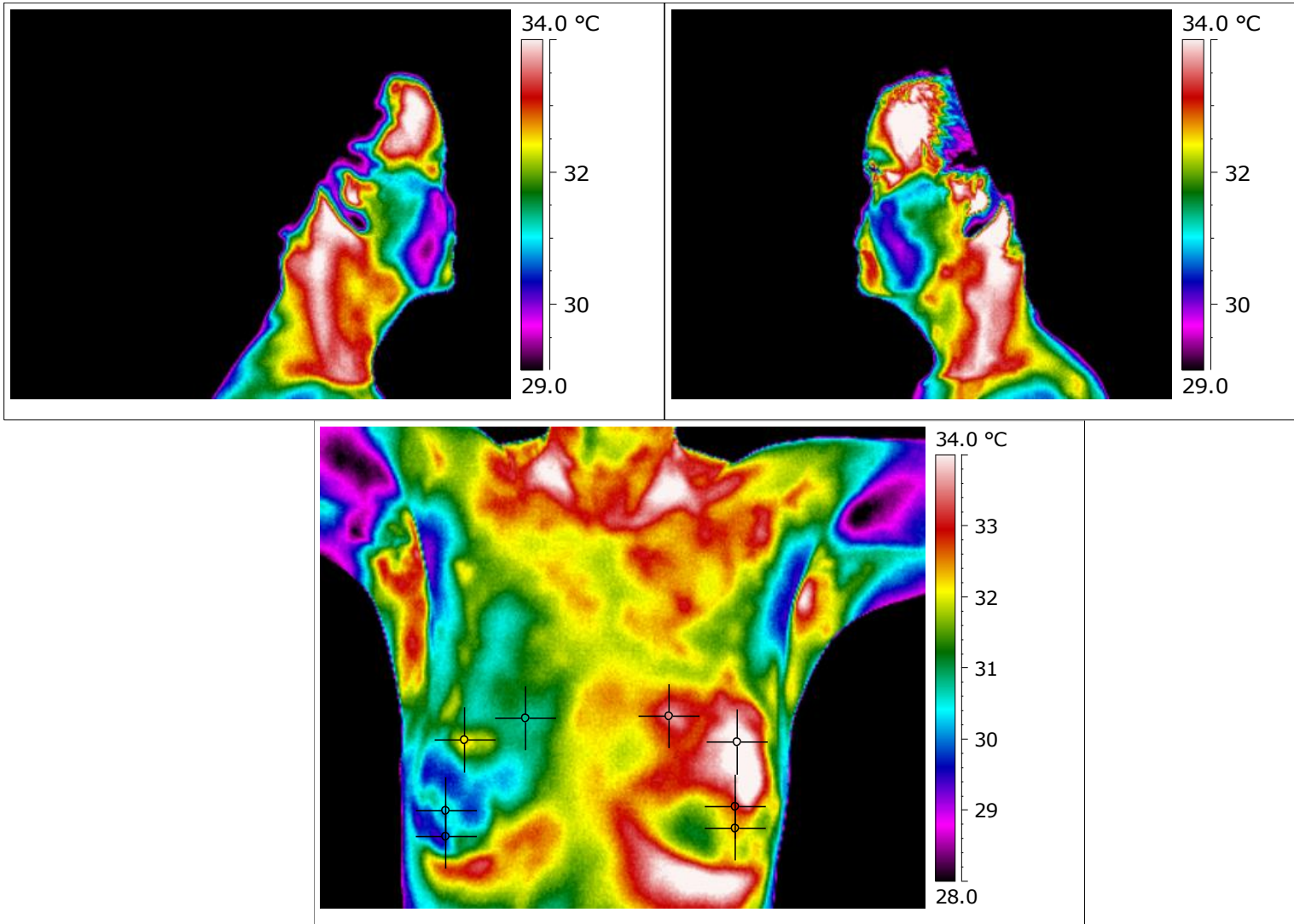


Case Study



Possible dental involvement lower left 3rd molar and lower left 1st premolar

Abnormal nipple and areolar temperatures and global hyperthermia

Left Breast cancer later confirmed